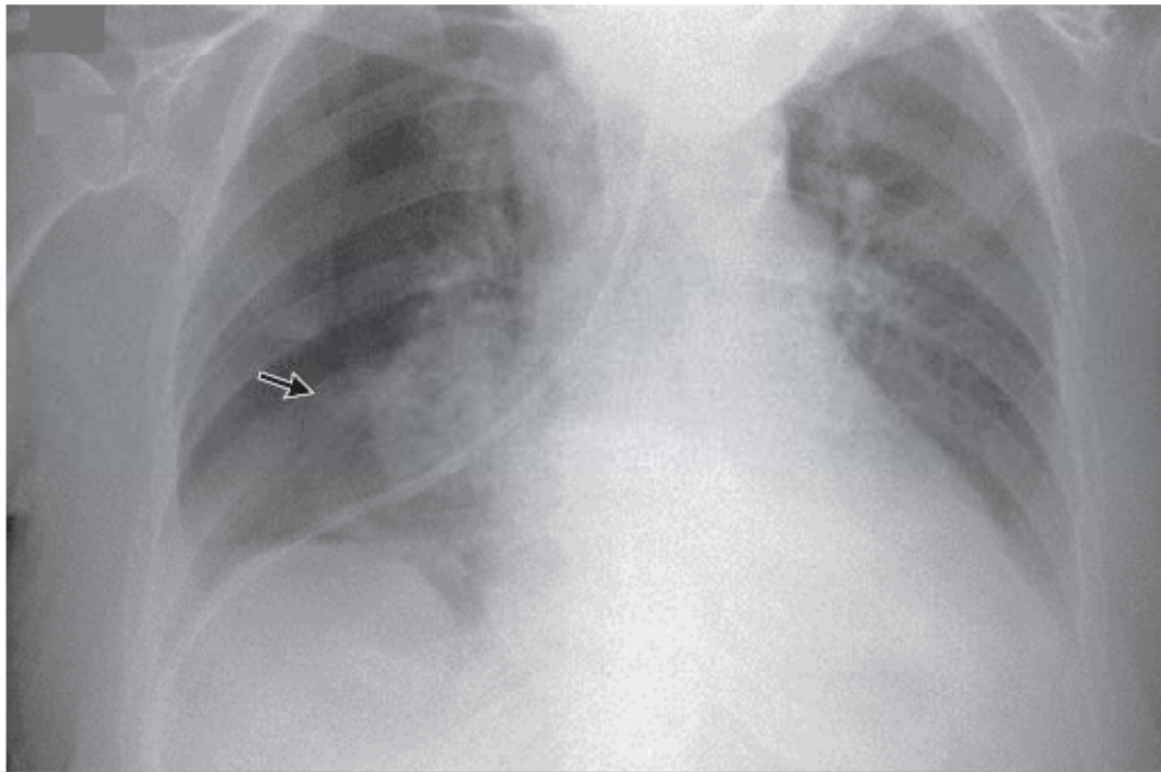


Instructions for Placing Nasogastric, Small Bowel Feeding Tubes Safely

IMAGES IN CLINICAL MEDICINE

Pneumothorax — An Uncommon
Complication of a Common Procedure



Why?

- Misplaced NG feeding tubes can occur
 - Numerous case reports in the literature
 - 3 in the past year at HUP
- A misplaced tube often leads to a preventable adverse event (iatrogenic pneumothorax)
- Education can prevent the vast majority of these complications



It appears you've swallowed a fly. Perhaps you'll die.

Materials Needed

- Feeding tube with guidewire (brown tip that is 120cm preferred over blue tip dobhoff tube)
- Lubricant
- 60 ml syringe

Steps for NG Feeding Tube Placement in an Awake Patient

Step 1: Measure tube from tip of nose to subxyphoid process (about 30-35cm in most patients)

Step 2: Place tube through nares and ask patient to swallow as you pass the tube

- Giving the patient a cup of water with a straw may help
- *IMPORTANT Patients may gag but should not cough.

If there is any coughing during this process, it is a warning sign that you may be in the airway rather than the esophagus

Steps for NG Feeding Tube Placement in an Awake Patient

Step 3: At 35 cm, STOP to confirm that tube is in esophagus and not mainstem bronchus. You can assess this through 2 methods:

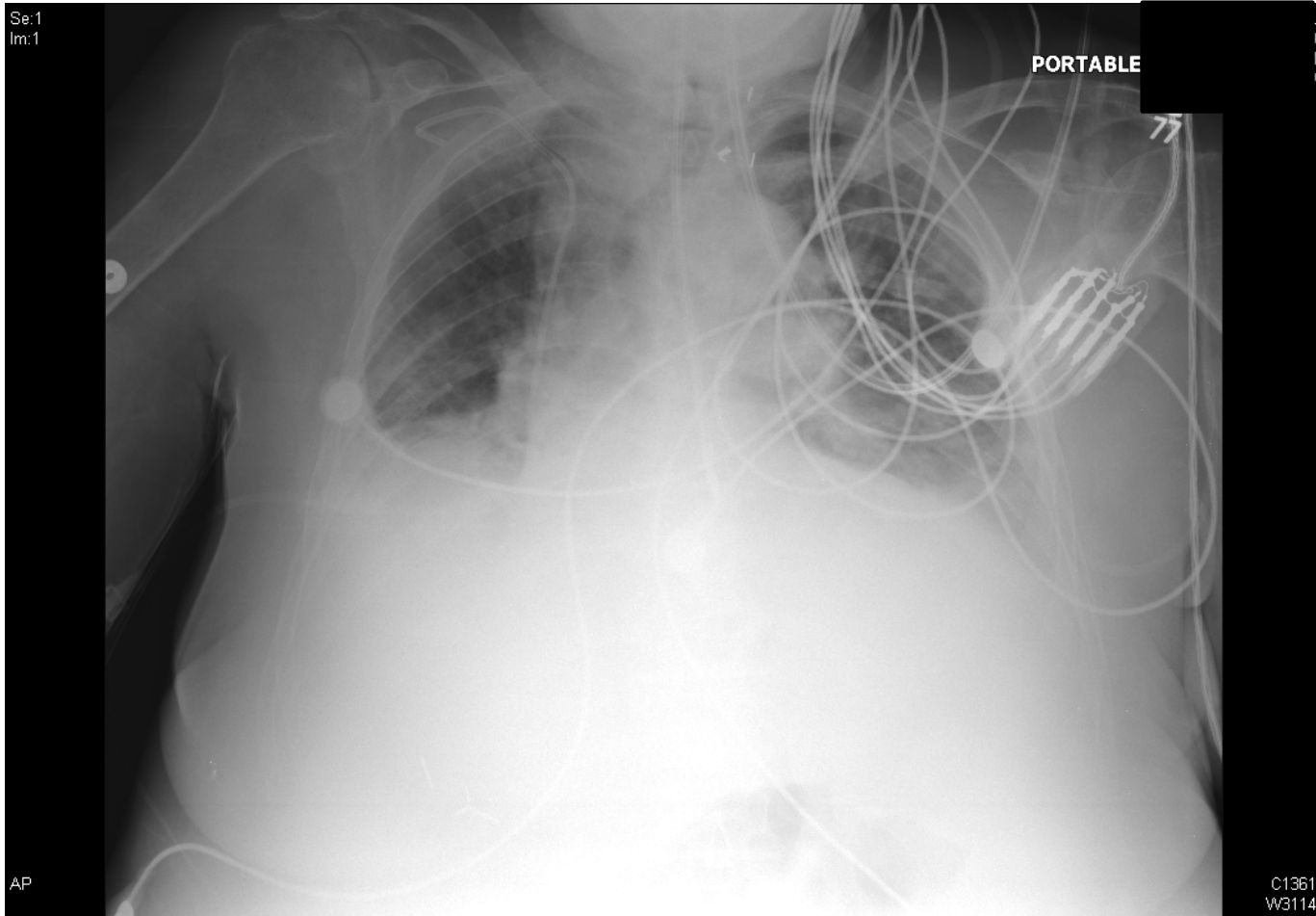
1. Get a CXR* (not an abdominal Xray)

OR

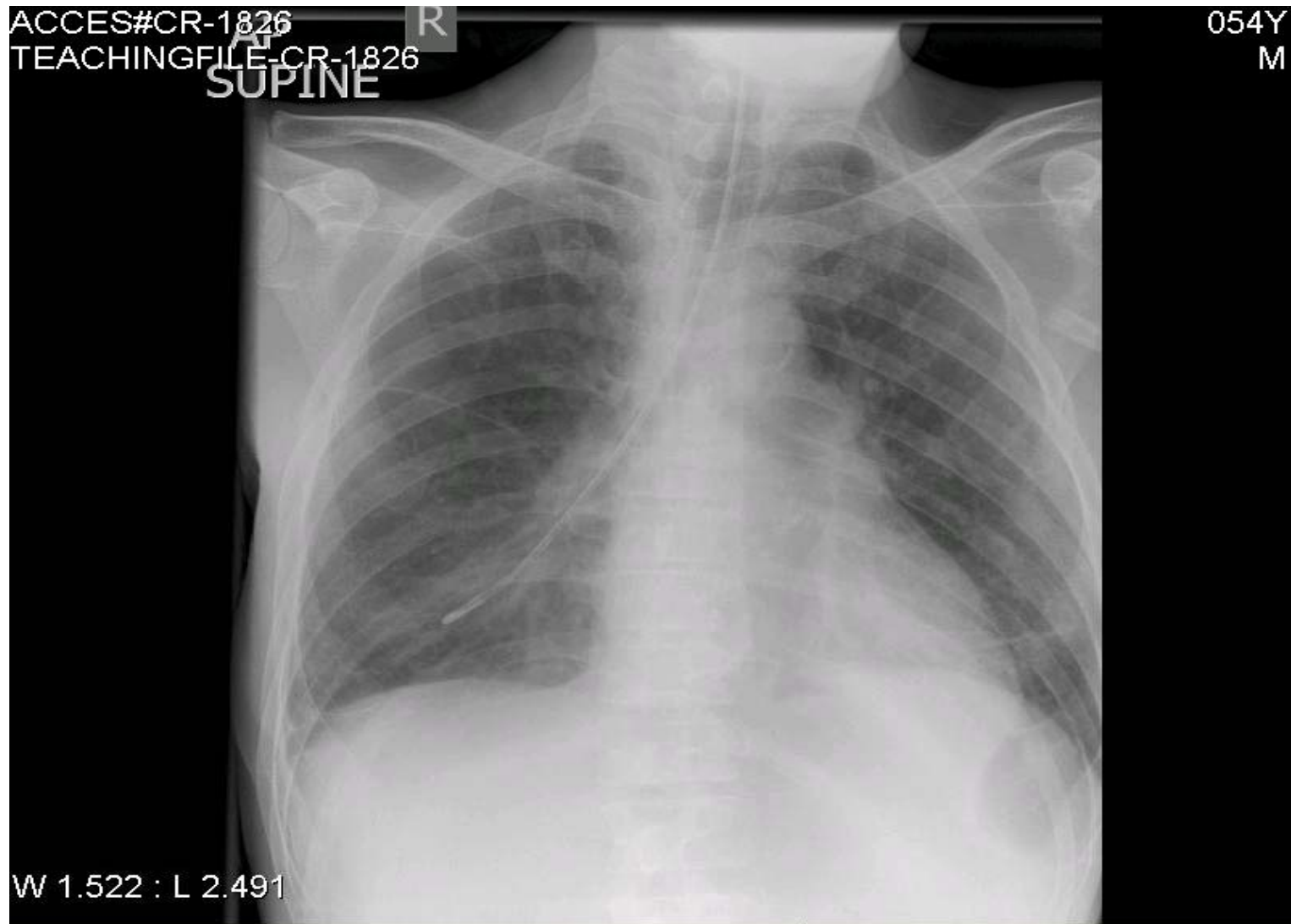
2. Place DHT under fluoroscopy

*If the feeding tube follows the path of the trachea and continues into the R or L mainstem bronchus, airway placement has occurred, and the tube should be pulled out and reinserted. GI placement is confirmed if you see the tube continuing straight below the carina on CXR (without following a bronchus)

Correct Placement



Incorrect Placement



Steps for NG Feeding Tube Placement in an Awake Patient

Step 4: Once confirmed DHT is past carina then advance DHT to stomach, check placement by insufflating with air, and then insufflate ~300cc of air into stomach to help open pylorus

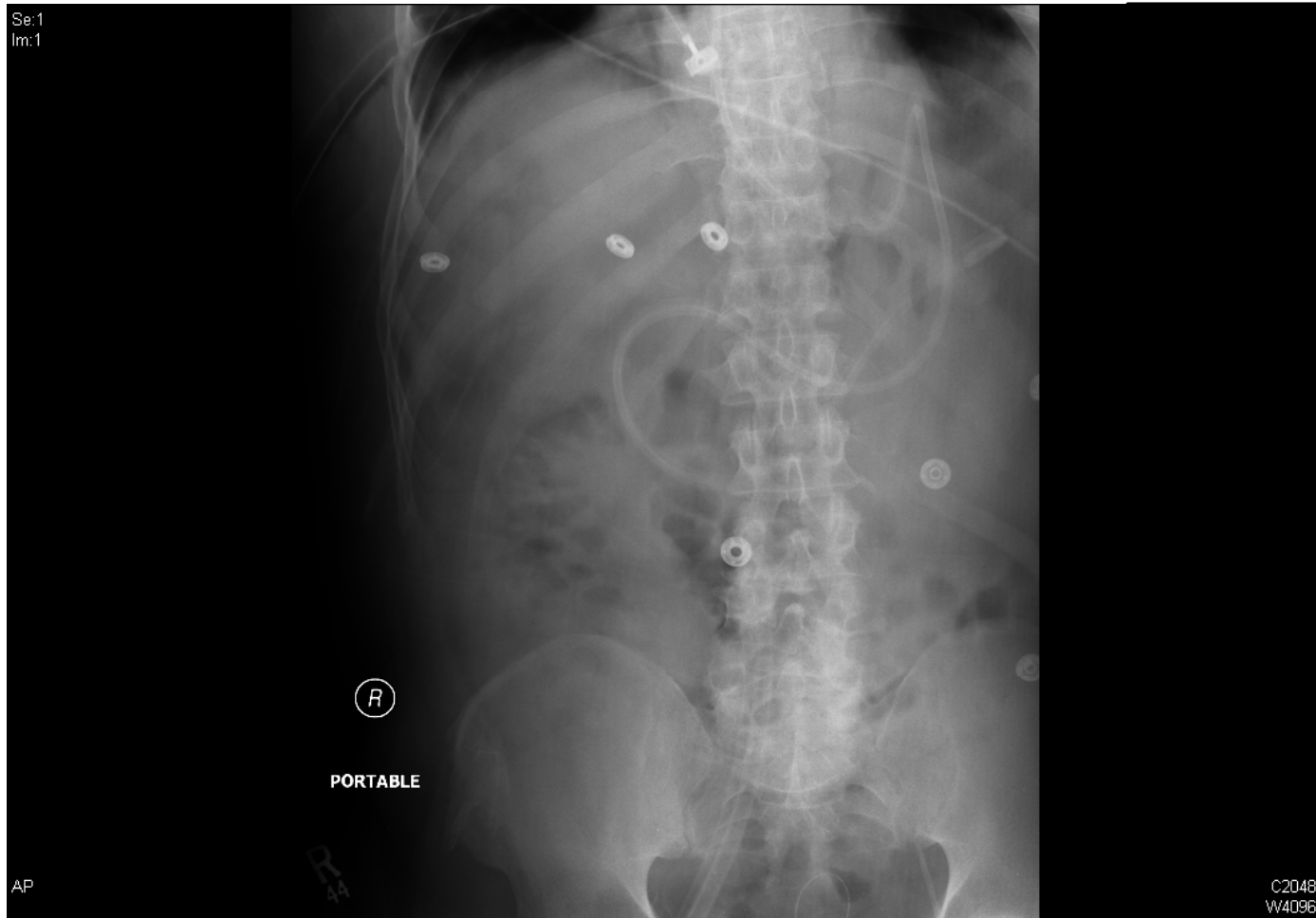Step 5: Advance DHT to about 80-100cm

Step 6: Leave guidewire in place and obtain an abdominal XRay

Steps for NG Feeding Tube Placement in an Awake Patient

- If tube is post-pylorus, secure tube to patients' nose
- If tube is not post-pylorus, re-attempt to advance tube with guidewire in place. Would consider promotility agent either prior to DHT placement or after first attempt if not successful. Reglan 10mg IV.
- Recheck KUB. If still not post-pyloric place patient on Reglan for ~12-24 hours and recheck KUB next day.

DHT Placed Post-Pyloric



What differs in an intubated/sedated patient?

- Decreased or absent cough reflex
 - due to neurologic injury or use of paralytic agents
 - Monitor tidal volumes, and saturation in intubated patient. If at ANY time tidal volumes drop, desaturation occurs or patient is coughing abort placement
 - In intubated patients DHT may become lodged on NGT in this case remove NGT and place DHT. Then place NGT.

Key Tips for Safety

- Measure nose to sub-xiphoid before starting
- Remove the tube at any point if any coughing
- Perform CXR at the point when at sub-xiphoid
- Do not rely on the sound of air insufflation to check correct position
- Always check the final X-ray reading before beginning tube feeds