

## Hepatic Artery Infusion for Colorectal Liver Metastases

► Surgeons and oncologists within the Department of Surgery at Penn Medicine are using adjuvant hepatic artery infusion (HAI) chemotherapy with systemic chemotherapy to prevent recurrence in patients with resected colorectal liver metastases (CLMs) or to treat unresectable CLMs.

The liver is both the most common site for CLMs to occur and the most common site of CLM recurrence following resection and chemotherapy, the mainstays of treatment for colon cancer metastases to the liver.

Approximately 75% of patients with CLMs will present with unresectable disease. Of patients with resectable disease, most will have a recurrence within three years. Thus, preventing recurrence and expanding the potential for tumor resection have become standard therapeutic objectives for patients with colorectal liver metastases.

One way to achieve these goals is to apply regional hepatic chemotherapy. Termed **hepatic artery infusion (HAI)**, the technique involves the continuous infusion of floxuridine (a pyrimidine analog) directly into the liver from a subcutaneous pump linked to a catheter surgically implanted in a branch of the hepatic artery (Fig. 1).

Floxuridine has a high first-pass extraction, so remains in the liver, providing a higher dose than would otherwise be possible.

At Penn Medicine, HAI is performed with systemic chemotherapy:

- In patients with resectable liver tumors, to reduce the chance of recurrence in the liver; and
- In most patients whose CLMs are deemed unresectable, to reduce tumor size; about a third of patients so treated will become resectable as a result.

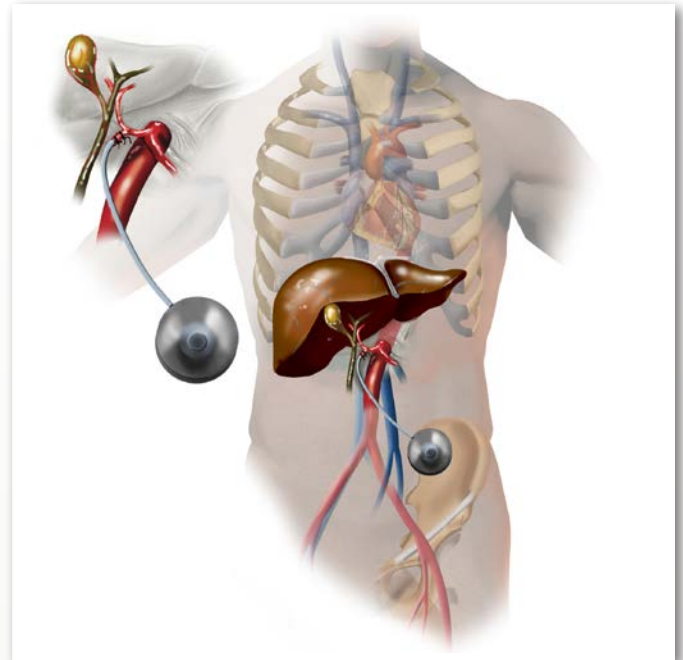
When combined with systemic chemotherapy, HAI has been found to significantly increase recurrence-free and overall survival in patients with previously resected colorectal liver metastases by comparison to surgery plus systemic chemotherapy alone. In a 2005 report, 41% of patients who received HAI with chemotherapy were alive 10 years after resection.<sup>1</sup>

In addition to CLMs, HAI can be performed as an adjunct to surgery for cholangiocarcinoma within the liver, where studies suggest outcomes similar to those for CLMs.<sup>2</sup>

### CASE STUDY

Mr. M, a 57-year-old man, was referred to Penn by his primary care provider after experiencing a substantial short-term weight loss (15 lbs over a two-week period) and blood in his stool.

A colonoscopy revealed a right colon cancer and a CT scan showed no evidence of spread to other organs. Mr. M was referred to Penn Surgery, and a week later, had a right hemicolectomy to remove the tumor. During this surgery 17 lymph nodes were also removed, which tested negative for metastatic disease. After counseling on the



► **Figure 1:** Hepatic artery infusion (HAI) involves the continuous infusion of floxuridine directly into the liver from a subcutaneous pump linked to a catheter surgically implanted in a branch of the hepatic artery.

importance of regular follow-up, Mr. M was discharged to home, and had an uncomplicated recovery.

Following a check-up at Penn twenty-three months later, however, Mr. M's carcinoembryonic antigen (CEA) level (a blood test that can correlate with tumor presence) was found to be elevated.

A subsequent PET-CT scan found two small (2cm) lesions in segment 6 of his liver. On further evaluation, these lesions were deemed resectable on the basis of size and position. Mr. M returned to Penn Surgery, and following a consultation on the nature of his disease and the risk of recurrence, he agreed to have HAI as an adjuvant to resection and systemic chemotherapy.

At surgery, following resection of the tumors, a catheter was introduced at Mr. M's gastroduodenal artery and linked to a hockey-puck-sized pump and reservoir implanted subcutaneously near his hip.

Mr. M remained in the hospital for two days, then returned home. At his one year follow-up, no sign of cancer recurrence was evident.

### References

1. Kemeny NE. Hepatic Arterial Infusion after Liver Resection. *NEJM* 2005;352:734-735.
2. Konstantinidis IT, Groot Koerkamp B, Do RK, et al. Unresectable Intrahepatic Cholangiocarcinoma: Systemic Plus Hepatic Arterial Infusion Chemotherapy is Associated with Longer Survival Compared to Systemic Chemotherapy Alone. *Cancer*. 2016 1;122:758-765.

## FACULTY TEAM

Penn Surgery is dedicated to high quality patient care, education, basic science and clinical research. The surgical faculty is composed of a diverse group of surgeons, subspecialists and researchers whose clinical, educational, and scientific activities are devoted to advancing the field of surgery and providing superlative surgical care to patients whatever their needs may be.

At Penn Medicine, **hepatic artery infusion** is performed by surgical oncologist Ronald DeMatteo, MD, Chair of the Department of Surgery, in collaboration with specialists from the Department of Endocrine and Oncologic Surgery, including Drs. Robert Roses and Kenneth Lee, and medical oncologists Drs. Charles Schneider, Thomas Karasic and Ursina Teitelbaum. For two decades, Dr. DeMatteo was on the faculty at Memorial Sloan Kettering Cancer Center in New York City, where HAI was developed in the 1980s.

### **Gastrointestinal Surgery**

#### [Ronald DeMatteo, MD](#)

*Chair, Department of Surgery  
John Rhea Barton Professor of Surgery*

#### [Major Kenneth Lee, MD, PhD](#)

*Assistant Professor of Surgery*

#### [Robert E. Roses, MD](#)

*Associate Professor of Surgery*

### **Medical Oncology**

#### [Thomas Karasic, MD](#)

*Assistant Professor of Medicine*

#### [Charles J. Schneider, MD, FACP](#)

*Clinical Professor of Medicine*

#### [Ursina R. Teitelbaum, MD](#)

*Clinical Director, Penn Pancreatic Cancer Research Center  
Deenie Greitzer and Daniel G. Haller Associate Professor*

## ACCESS

### [Penn Gastrointestinal Surgery Perelman 4th Floor](#)

Perelman Center for Advanced Medicine  
West Pavilion, 4th Floor  
3400 Civic Center Boulevard  
Philadelphia, PA 19104  
215.662.2626

### [Penn Endocrine and Oncologic Surgery Perelman 3rd Floor](#)

Perelman Center for Advanced Medicine  
South Pavilion, 3rd Floor  
3400 Civic Center Boulevard  
Philadelphia, PA 19104  
215.662.2626

### [Abramson Cancer Center Perelman 2nd Floor West](#)

Perelman Center for Advanced Medicine  
West Pavilion, 2nd Floor  
3400 Civic Center Boulevard  
Philadelphia, PA 19104  
215.615.5858

