



Penn Medicine

3600 Civic Center Boulevard
Suite 500
Philadelphia, PA 19104

Non-Profit Org.
U.S. Postage
PAID
Permit No. 2563
Philadelphia, PA

PENN CLINICAL BRIEFINGTM

▶ Alternative Treatments for Patients with CPAP-Refractory Obstructive Sleep Apnea

Alternative Treatments for Patients with CPAP-Refractory Obstructive Sleep Apnea

► Penn Medicine has developed a comprehensive CPAP Alternatives Clinic to diagnose and treat patients who are refractory to first- and second-line therapies for obstructive sleep apnea (OSA), including continuous positive airway pressure (CPAP) therapy.

Led by Raj C. Dedhia, MD, MSCR, one of the first ten otolaryngologists in the nation to complete a fellowship in sleep medicine, the new Clinic offers a comprehensive selection of diagnostic techniques and advanced surgical procedures with the mission of restoring sound sleep to individuals deprived of the option of CPAP therapy.

CPAP is the first-line therapy for adults with moderate-to-severe OSA. It is estimated, however, that 50% of CPAP users are nonadherent within one year, either because they cannot tolerate the devices or see no improvement with treatment.

Evidence suggests that use of CPAP will improve with counseling in about a quarter of nonadherent patients. For the remainder—patients who are refractory to CPAP—a variety of options are now available at Penn.

Diagnosis of CPAP-Refractory OSA

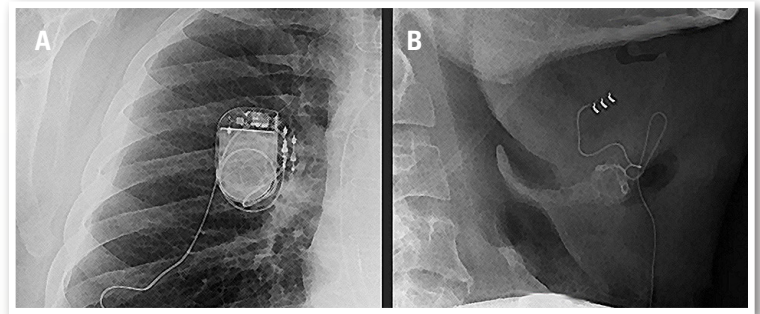
On entering the Penn CPAP Alternatives Clinic, most patients will receive a meticulous diagnostic evaluation to determine the cause of CPAP intolerance.

The process begins with a physical examination of the nasal cavity to identify, if possible, the site and severity of airway obstruction. If no obstruction is found in the nasal cavity, an in-depth review of past sleep studies is performed, including an analysis of overnight raw data related to airflow and oxygen saturation. The patient's medical history is also reviewed, and a supine nasolaryngoscopy performed. This quick, painless procedure uses a flexible scope to examine the nose and throat for physical abnormalities.

If the nasolaryngoscopy fails to reveal an obvious source of obstruction, a confirmative diagnosis may be achieved by drug-induced sleep endoscopy, or **DISE**, a study performed under sedation to evaluate the sites and patterns of airway collapse seen in patients with OSA. This information is then used to determine eligibility for specific second-line therapies.

A further refinement, involving the administration of PAP during DISE (or **DISE-PAP**) provides dynamic evaluation of PAP therapy effects on the upper airway anatomy to predict who will respond to hypoglossal nerve stimulation.

(Continued on the back)



► **Figure 1:** (A) Postoperative radiographs of hypoglossal nerve stimulation device implanted at the right chest wall and neck.

CASE STUDY 1

Mrs. V, a 60-year-old normal-weight female, was referred to the Penn CPAP Alternatives Clinic after a series of mishaps with her CPAP devices, including difficulties with the auto-set on her machine, swallowed air, and other discomforts. She had previously been diagnosed with moderate obstructive sleep apnea with an Apnea-Hypopnea Index (AHI) of 24.

At Penn, a thorough physical exam found that Mrs. V had poor dentition (and could not therefore receive a mouth appliance), and her history precluded oral surgery. Based upon her anatomy, tongue size, age and AHI, she was, however, a good candidate for hypoglossal nerve stimulation. A DISE-PAP was performed, which revealed that most of the obstruction was from her tongue. Following a consultation to explain the procedure and its potential risks, Mrs. V agreed to have the procedure to implant the device.

Following implantation (Figure 1) Mrs. V returned for two- and four-week follow-up visits, during which satisfactory healing was noted. At the second of these visits, her device was activated, and she was given an independent remote and instructed to gradually advance her device to therapeutic levels over the next 30 days.

At 30 days, she returned to the sleep lab at Penn for a titration study to determine how well the therapy was working, and reported that she was experiencing deep, satisfying sleep, and had stopped snoring. The results of her sleep study showed that her AHI was now 9, or below the level of cardiovascular risk, a finding confirmed in a whole night home sleep test. These results were consistent at her 3, 6 and 12 month follow-up visits.

CASE STUDY 2

Mr. G, a 46-year-old man, was referred to the Penn CPAP Alternatives Clinic by his ENT after falling asleep repeatedly behind the wheel of his school bus. Mr. G was obese (BMI 32), but was otherwise healthy, and had no sleep-modulating medical comorbidities. At Penn, he reported that he had not slept consistently or well for several years. During this time, his treatments included failed attempts at CPAP and a mouth appliance, and to address palatal obstruction, a tonsillectomy and uvulopalatopharyngoplasty. The latter, which involves removing tissue from the soft palate and throat and a painful recovery, moved Mr. G's sleep apnea number from 55 to 50.

On examination, Mr. G was found to have a large tongue base and relatively small jaws. A further complication arose when a DISE-PAP sleep endoscopy study discovered complete circumferential palatal collapse, the sole contraindication to hypoglossal nerve stimulation.

(Continued on the back)

Second-Line Treatments for CPAP Refractory Sleep Apnea

The Penn CPAP Alternatives Clinic offers a wide spectrum of treatment options for patients who are resistant to first-line CPAP therapy. The initial approach for many patients will involve weight loss, positional therapy, and other conservative measures, including custom-fitted oral appliances that alter jaw position during sleep.

Patients who do not respond to these therapies may benefit from an array of surgical options that target the physical causes of sleep apnea. Thus, the Clinic offers surgeries for obstruction originating in the nasal cavities, the jaw and throat, and the tongue and epiglottis.

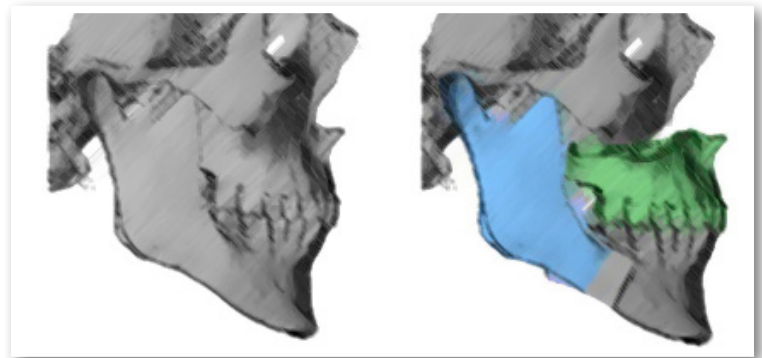
The CPAP Alternatives Clinic is among the few in the region to offer the following advanced procedures:

- **Hypoglossal Nerve Stimulation** employs an implanted device that works by stimulating the protrusion branches of the hypoglossal nerve (tongue motor nerve) during the collapse-prone portion of the respiratory cycle to restore upper airway muscle tone. The device contains leads that monitor breathing patterns during sleep and deliver mild, rhythmic stimulation to the hypoglossal nerve when obstruction occurs.
- **Distraction Osteogenesis Maxillary Expansion (DOME)** expands the upper jaw to improve airflow when the oral vault is too narrow.
- **Transpalatal Advancement Pharyngoplasty** is an advanced option for treating soft palate collapse, involving the removal the back of the hard palate to shift the soft palate forward and open the airway.
- **Maxillomandibular Advancement (MMA)** involves moving the upper and lower jaws forward to enlarge the airway for patients whose apnea is caused by collapse of the side walls of the throat.

Dr. Dedhia welcomes referrals from sleep physicians, sleep dentists, ENTs, and cardiologists who have patients with arrhythmia (atrial fibrillation) and sleep apnea, and is available to assist cardiologists, neurologists and anesthesiologists when OSA presents in their patients.

ACCESS

Penn Otorhinolaryngology – Head and Neck Surgery
 Perelman Center for Advanced Medicine
 3rd Floor, South Pavilion
 3400 Civic Center Boulevard
 Philadelphia, PA 19104



► **Figure 2:** Maxillomandibular Advancement (MMA) surgery moves the upper and lower jaws forward to enlarge the airway.

(Continued from cover)

Given his physiology, and having been denied the anticipated benefits of CPAP, oral appliances and two surgeries, Mr. G became a candidate for maxillomandibular advancement (MMA). A significant surgery, MMA achieves enlargement of the airway by advancing the maxilla and mandible (Figure 2), which moves the muscular attachments of the hard palate, tongue and soft palate forward.

MMA is a very successful treatment for OSA, but can be associated with rare complications, and careful postoperative care is warranted. Mr. G was provided with written materials and asked to consider his options carefully. At his next visit, Mr. G agreed to have the surgery, which was scheduled to coincide with the end of the school year.

In preparation for surgery, Mr. G came in for pre-surgery evaluations, CAT scans, and 3D modeling to simulate the existing and proposed alterations in jaw position. These resulted in a successful procedure and uncomplicated recovery. At his first follow-up visit, Mr. G reported a dramatic improvement in sleep and energy, a report reinforced by a sleep study at four months post-surgery documenting a decline in AHI from 55 events/hour to 7.

FACULTY TEAM

The Department of Otorhinolaryngology-Head and Neck Surgery and Penn Sleep Center CPAP Alternatives Clinic is directed by Raj Dedhia, MD, MSCR. The Clinic's mission is to offer options for treatment to the 50% of individuals who are refractory to CPAP, and to those patients who have exhausted the common second-line therapies for obstructive sleep apnea.

► Providers

Raj C. Dedhia, MD, MSCR
 Director, Division of Sleep Surgery
 Penn Otorhinolaryngology - Head & Neck Surgery
 Director, CPAP Alternatives Clinic, Penn Sleep Center

Erica Thaler, MD
 Director, Division of General Otorhinolaryngology
 Director, Otorhinolaryngology Outpatient Surgical Practices,
 Hospital of the University of Pennsylvania

Richard J. Schwab, MD, DABSM
 Co-Medical Director, Penn Sleep Center at 3624 Market Street
 Professor of Medicine at the Hospital of the University of Pennsylvania